

# Bulletin de la Dialyse à Domicile

## Surgical technique for peritoneal dialysis catheters implantation. Experience of a center

(Technique d'implantation chirurgicale des cathéters de dialyse péritonéale.  
Expérience d'un centre)

Olivier Develay<sup>1</sup>, Mohamed Rifaat<sup>2</sup>, Seddik Benarbia<sup>2</sup>, Stephen Caramaro<sup>1</sup>

<sup>1</sup>Clinique Saint Michel Sainte Anne, 88 rue de Kerjestin 29000 QUIMPER

<sup>2</sup>Centre de dialyse AUB santé Z.I, 4 Rue Georges Perros, 29000 QUIMPER

Note : ce texte est disponible en Français à la même adresse url : <https://doi.org/10.25796/bdd.v4i4.63213>

### Résumé

Alors que la réalisation d'un abord vasculaire est un acte fréquent pour un chirurgien qui travaille avec un centre d'hémodialyse, l'implantation d'un cathéter de dialyse péritonéale s'avère souvent plus rare en raison d'un nombre inférieur de patients incidents pris en charge en dialyse péritonéale (DP). Certains centres vont parfois avoir moins de dix nouveaux patients par an traités par DP ; lorsque un chirurgien débute cette activité, il est important que sa technique d'implantation du cathéter de DP soit d'emblée maîtrisée pour permettre au néphrologue de prendre en charge son patient dans les meilleures conditions avec un cathéter de DP fonctionnel quelle que soit la modalité de DP. L'implantation en ambulatoire, sous anesthésie locale ou générale, permet de limiter la durée d'hospitalisation. L'utilisation de cathéters en col de cygne à extrémité droite, un trajet pré péritonéal tangential, la vérification fonctionnelle per opératoire terminée par une introduction de 100 ml de sérum physiologique, une première réfection du pansement et une première utilisation au dixième jour permettent dans notre expérience d'avoir un cathéter fonctionnel dans 93,5 % des cas.

Mots clés : dialyse péritonéale, cathéter, laparotomie, technique chirurgicale, placement cathéter

### Summary

While performing a vascular approach is a frequent act for a surgeon working with a hemodialysis center, the implantation of a peritoneal dialysis catheter is often less frequent due to a lower number of incident patients : some centers will sometimes have less than ten new patients per year treated with PD; When a surgeon begins this activity, it is therefore important that his PD catheter implantation technique is mastered from the outset to allow the nephrologist to take care of his patient in the best conditions with a functional PD catheter regardless of the PD modality. The catheter implantation on an outpatient basis, under local or general anesthesia, makes it possible to limit the duration of hospitalization. The use of swanneck catheters with a straight extremity, a tangential pre-peritoneal path, the pre-operative functional check completed by an introduction of 100 ml of dialysate, a first repair of the dressing and a first use on the tenth day allow, in our experience, to have a functional catheter in 93.5% of cases.

Key words : peritoneal dialysis, operation, open surgery, catheter placement

**How to Cite:** Develay O, Rifaat M, Benarbia S, Caramaro S. Surgical implantation procedure for peritoneal dialysis catheters. Experience of a single center. Bull Dial Domic [Internet]. 2021 Nov;4(4):289-00. Available from: <https://doi.org/10.25796/bdd.v4i4.63213>

## INTRODUCTION

Much like the arteriovenous fistula for patients treated with hemodialysis, the proper functioning of the catheter is the Achilles' heel of peritoneal dialysis. It depends on many factors, often intertwined and that cannot always be controlled: the shape of the catheter, the patient's build, the tolerance of the organism, the conditions of asepsis and its use in postoperative care, the implantation technique, and the operator's experience. Many studies have previously described the implantation technique, some interventions having been carried out by the nephrologist, generally by the cutaneous route with the use of a trocar; others by the surgeon either by a laparoscopic approach or by laparotomy, under local or general anesthesia. The realization of the arteriovenous fistula is usually carried out by a vascular surgeon or a urologist, and the implantation of the peritoneal dialysis catheter by a digestive surgeon or a urologist. We report in this article our experience on introducing peritoneal dialysis catheters, in the clinic Saint Michel Sainte Anne de Quimper. All of the operations took place between 2014 and 2021, and were performed by the same surgeon. This is a seemingly simple intervention that however requires some basic precautions so that the nephrology team can then prescribe peritoneal dialysis without having to worry about the catheter.

## METHODS

### Preoperative consultation

- During the consultation, a search for a surgical history and a clinical examination of the abdomen and pelvis are carried out. Potential difficulties in placing the catheter can thus be apprehended, e.g. scars from previous surgeries, prosthetic material previously placed to repair the abdominal wall, or an abdominal wall hernias.

- During this consultation, the side of the emergence location of the catheter is defined according to the choice of the patient and the location of the equipment for home dialysis. The patient is given a written document reminding them of the procedure of catheter implantation, its risks and possible complications. A written record of the delivery of the document to the patient is kept in the file and the collection of his consent is essential for the operation to be carried out.

- At the end of the consultation, the patient is referred to the anesthesiologist and the intervention date is scheduled. Usually the patient's stay is outpatient. During their consultation, the anesthesiologist decides on the type of anesthesia, either general or local, potentiated by intravenous sedation.

- The preoperative management of anticoagulant and antiplatelet therapies follows the recommendations of the SFAR (French Society of Anesthesia, <https://sfar.org>):

Treatments with 75mg acetylsalicylic acid are thus maintained.

The intake of clopidogrel is conventionally interrupted five days before the scheduled surgery and replaced by a daily intake of 75mg acetylsalicylic acid, except in patients with one or more recent active coronary stents in which case the cardiologist's opinion is requested. For patients treated with anticoagulants and in particular direct oral anticoagulants (DOA) (Xarelto®, Pra-

daxa®, Eliquis®): their treatment is interrupted five days before the scheduled surgery; In the event of a moderate thrombotic risk (atrial fibrillation without any embolism background, moderate-risk venous thromboembolic disease (VTE)) a relay with heparin is not offered.

In the event of a high thrombotic risk (pulmonary embolism in the last 3 months, proximal venous thrombosis in the last 3 months, idiopathic recurrent VTE, atrial fibrillation with history of stroke or cardiological requirement, mechanical heart valves) a relay by LMWH s/c 100 IU antiXa/kg/12 h or 0.01ml/kg/12 h is ensured on D-3, D-2, and D-1 (morning) and is stopped 24 hours before the intervention if the clearance according to cockroft is higher than 40ml/min . In case of a clearance below 40 ml/min CALCIPARINE s/c 250 IU/kg/12h is provided on D-3, D-2 and D-1 morning and evening, and is stopped 24 hours prior to the operation or unfractionated heparin (TCA: T x 2 to 2.5) and is stopped 5 hours before the intervention.

The performing of a NFS platelet blood test on D-1 is required.

### **Outpatient care on the day of the operation**

On the day of the operation, the patient is summoned to the surgical reception unit two hours before their surgery, the reception nurse ensures their identity, the realization at home of the pre-operative shower and their fasting according to the current recommendations of the SFAR. The operated person is asked to empty their bladder prior to the operation.

The operated person walks to the entrance of the surgical unit in the company of a nursing assistant. They are then moved to the operating room on a stretcher.

### **Anesthesia and preparation**

Once the patient is positioned on the operating table, a peripheral venous line is set in place. If the patient bears an arteriovenous fistula (AVF), the opposite arm will be chosen. In all cases, we will try and choose a vein that is as peripheral as possible in order to save vascular capital in these patients who may still subsequently need an AVF.

Once placed, the peripheral venous route allows drugs to be injected for either general anesthesia or sedation which will accompany local anesthesia.

Patients who cannot benefit from general anesthesia due to a fragile background (in particular patients whose indication for placement is refractory heart failure) will have the catheter inserted under local anesthesia potentiated by heavy intravenous sedation. This intravenous sedation most often involves the administration of Remifentanil (a potent intravenous morphinic) by intravenous programming according to sex, age, weight and height in order to maintain spontaneous ventilation (TCI mode). The injection of remifentanil is supplemented by a continuous intravenous injection of ketamine and lidocaine.

An antibiotic prophylaxis by intravenous injection of 2g of Cefazolin is performed.

The operated person is placed in the supine position. If she is a woman, the gynecological position enabling a possible bladder catheterization is preferred.

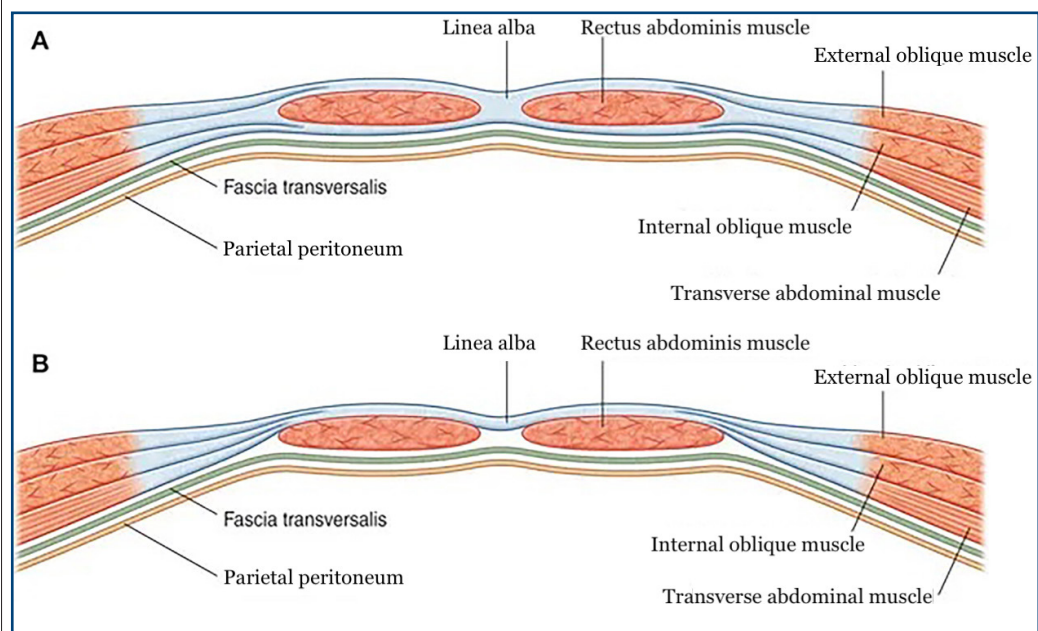
If deemed necessary by the surgeon, a mechanical hair removal is performed on the abdomen. Detergent is only used on soiled skin. The disinfection of the abdomen is carried out using an antiseptic in alcoholic solution. The surgeon and his assistant have the operating drapes set before checking the operating checklist.

### Choice of the type of catheter

The catheter we use is the 43-cm-long straight Swan-Neck Tenckhoff catheter with two cuffs.

## OPERATING TECHNIQUE

The technique stems directly from the anatomy of the anterior abdominal wall, as exposed in figure 1 below.

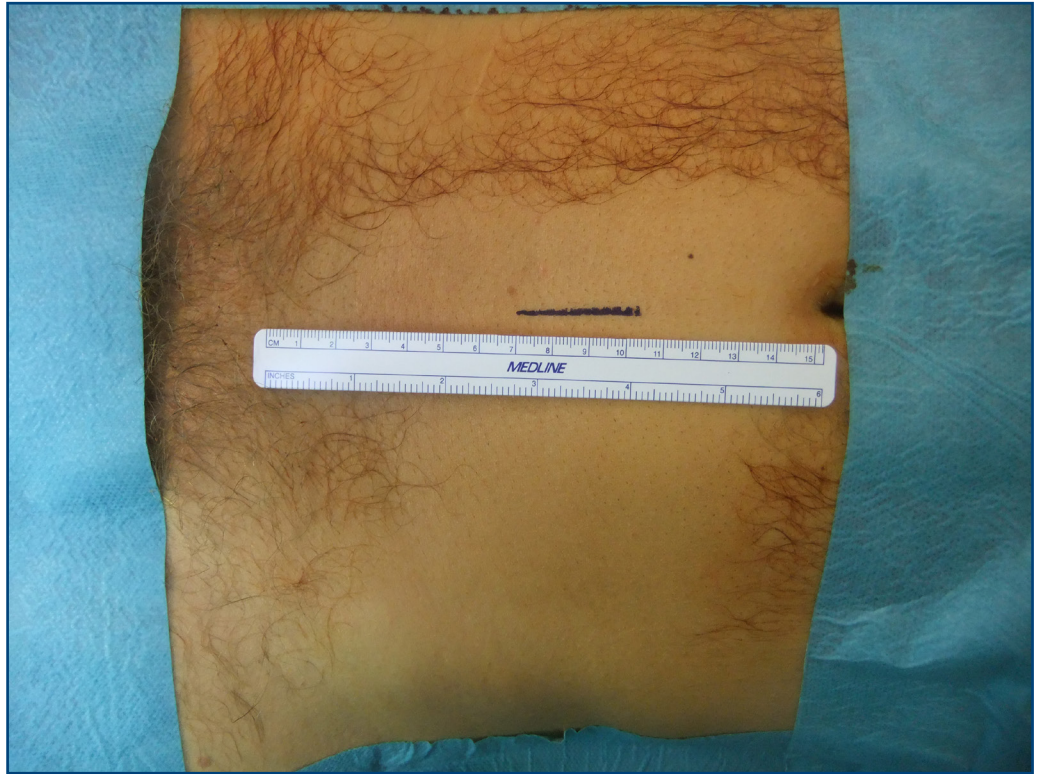

↑ Figure 1. Section A goes through the upper part of the abdomen. In B, the section goes through the lower part of the abdomen and shows the different planes that the surgeon will encounter when placing the peritoneal dialysis catheter as described below

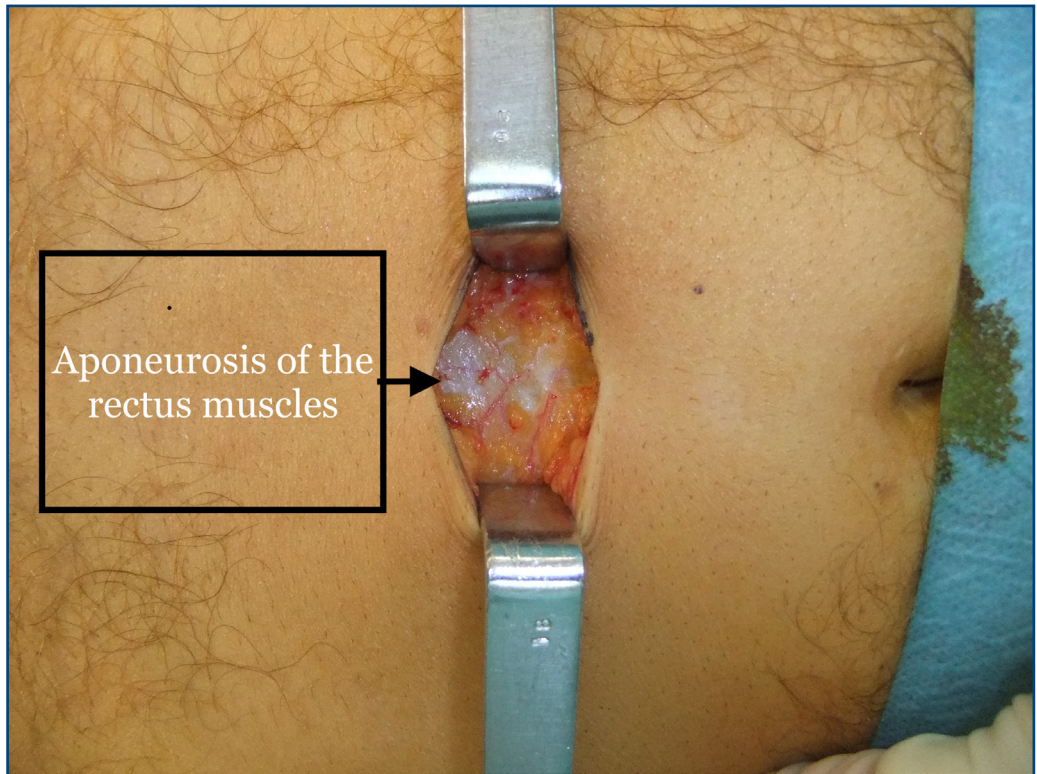
A 3-cm-long skin incision is made in the midline with a scalpel blade. Its lower end is located halfway between the umbilicus and the pubis. (figure 2)

A monopolar electric scalpel is then used except in the case of a cardiac pacemaker (the bipolar scalpel is used in that case), allowing the opening of the subcutaneous cellular-fatty tissue and the superficial fascia, thus allowing in turn the exposure of the aponeurosis of the rectus muscles. ( Figure 3).





↑ Figure 2. Tracing of the midline incision line under the umbilicus

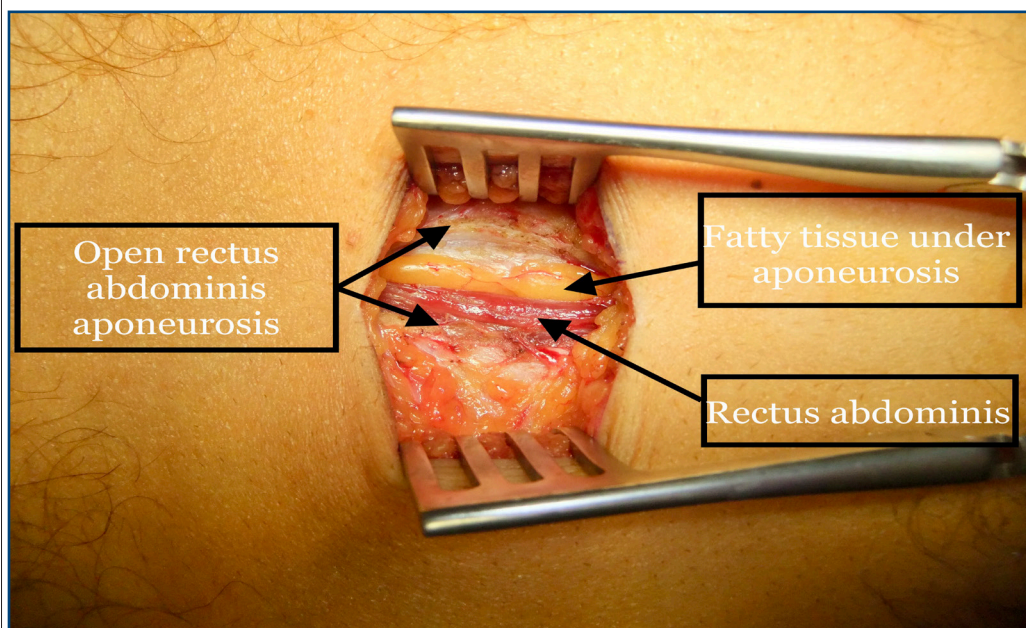


↑ Figure 3. Exposure of the aponeurosis of the rectus muscles on the linea alba

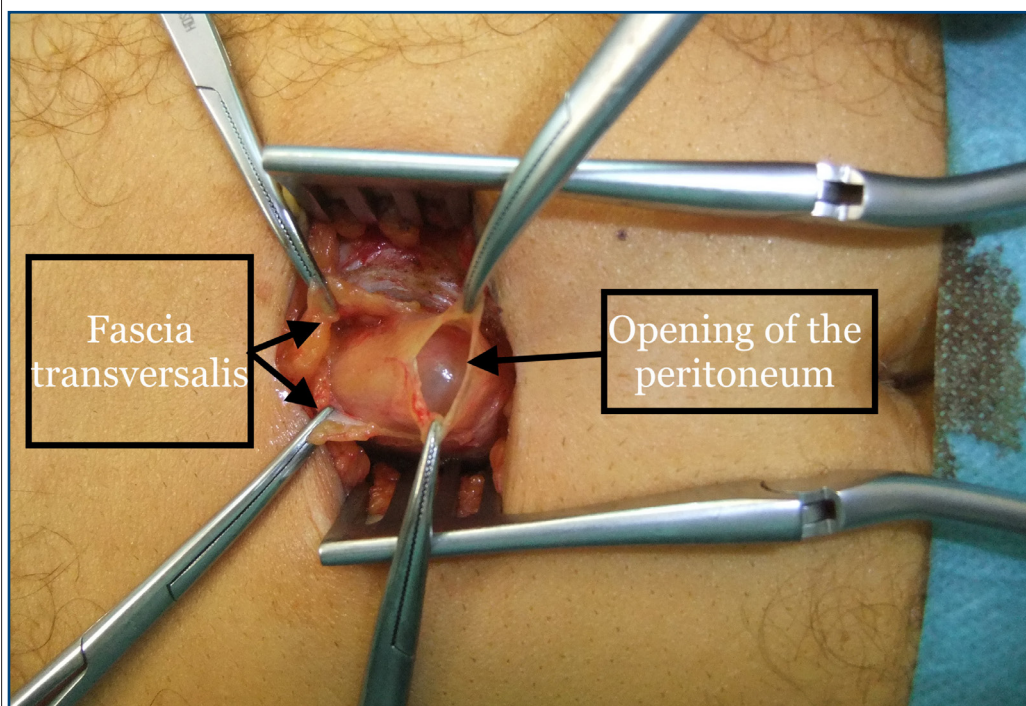


The fatty tissue under aponeurosis (Figure 4) and the fascia transversalis are opened, and the peritoneum is exposed after it has been opened with a fine chisel over 5 mm (Figure 5). The peritoneum's edges are grasped by two forceps and pulled at the zenith by the operating aid.

In the event of a cardiac indication during the setting in place of the dialysis catheter, it is common after opening the peritoneum to drain a sometimes large quantity of ascitic fluid which is sampled with a syringe for the purpose of systematic bacteriological examination.



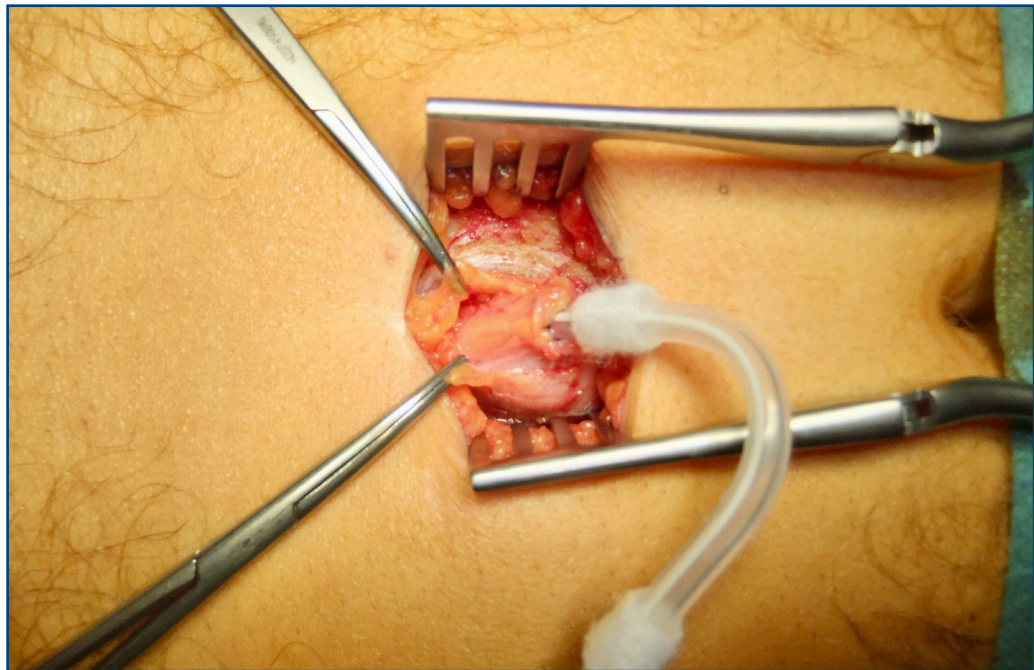
↑ Figure 4. Exposure of the different planes after the opening of the fascia of the rectus abdominis muscles



↑ Figure 5. Opening of the peritoneum

An absorbable 3/0 thread bursa is created at the opening of the peritoneum.

Introduction towards the rectouterine pouch of the TENCKHOFF catheter mounted on a metal rod is introduced towards the rectouterine pouch. The progression of the catheter must be done delicately without meeting resistance and following an initially vertical trajectory then at 45° pointing towards the rectouterine pouch. The metal rod is removed, while the operator checks that the catheter does not tend to come out, then the peritoneal bursa is closed around the end of the catheter deep extraperitoneal cuff.(Figure 6).



↑ Figure 6. Introduction of the peritoneal dialysis catheter, its deep cuff is positioned above the peritoneum

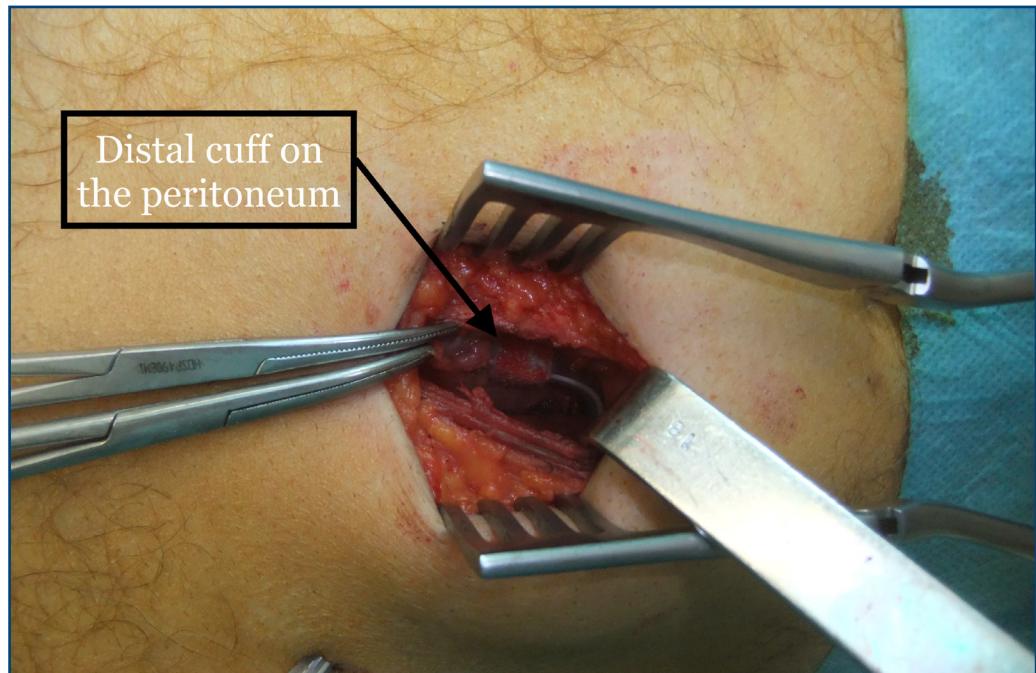
The proper functioning of the catheter is then verified thanks to the injection of 100ml of physiological serum and the observation of its drainage in a slanting position, without ever aspirating so as not to attract any omental fringes in contact with the catheter.

The rectus abdominis is detached, tilted upwards by a Farabeuf retractor and the distal end of the catheter mounted on a Redon awl is visually controlled, taking care not to injure the epigastric pedicle during the transrectal passage of the awl. Thus the initial pre-peritoneal path of the catheter is tangential to the peritoneum, with the catheter lying on it until it passes through the rectus muscle laterally with respect to the median.

It is important to verify the absence of bleeding on the posterior surface of the rectus muscles (tilted upwards by a Farabeuf retractor) after the trans rectal passage of the awl.

The tunneling path is oriented downwards and outwards according to the shape of the catheter and at a distance of approximately 4 to 5cm from the midline incision in order to limit the risk of the catheter kinking. (Figure 7).





↑ Figure 7. Appearance after the tunneling of the catheter

The superficial cuff will thus have a position in the rectus muscle or in the subcutaneous plane following this tunneling path.

In our experience, the positioning of the superficial cuff in the rectus muscle did not cause discomfort, nor did it generate infectious complications.

The incision of the aponeurosis of the rectus abdominis muscles is closed with a suture of absorbable 2/0 suture.

The superficial fascia is closed with separate points of absorbable 2/0 thread.

Skin closure with a fast absorbing 4/0 thread overlock.

The proper functioning of the catheter is checked thanks to an injection of 50 to 100 ml of physiological serum so as not to end up with drainage, which is a source of postoperative obstruction.

A self-fixing hydrocellular absorbent dressing (Mepilex Border) is placed on the median scar and on the point of emergence of the catheter, this one being rolled in a spiral and covered with compresses and a transparent adhesive film (Tegaderm) 15x20cm .

Once the operation is completed, the patient is taken to the recovery room for monitored surveillance.

Finally, the surgeon visits the patient in their room and allows their return home.

The nephrologist is sent an operative report specifying that the carrying out of postoperative washings is unnecessary, and that it is recommended to wait 10 days before re-dressing and / or using the catheter if possible.

In the case of catheters placed for cardiac indications and in the presence of ascites, daily drai-



nage of the ascitic fluid through the catheter is carried out immediately as postoperative cares in order to avoid leaks and ensure healing during a period of ten days before starting the exchanges.

The patient is systematically summoned to the dialysis center the day following his intervention to check the dressing.

## RESULTS

Between April 2014 and April 2021, 60 operations to insert a peritoneal dialysis catheter were performed at the clinic by the same operator.

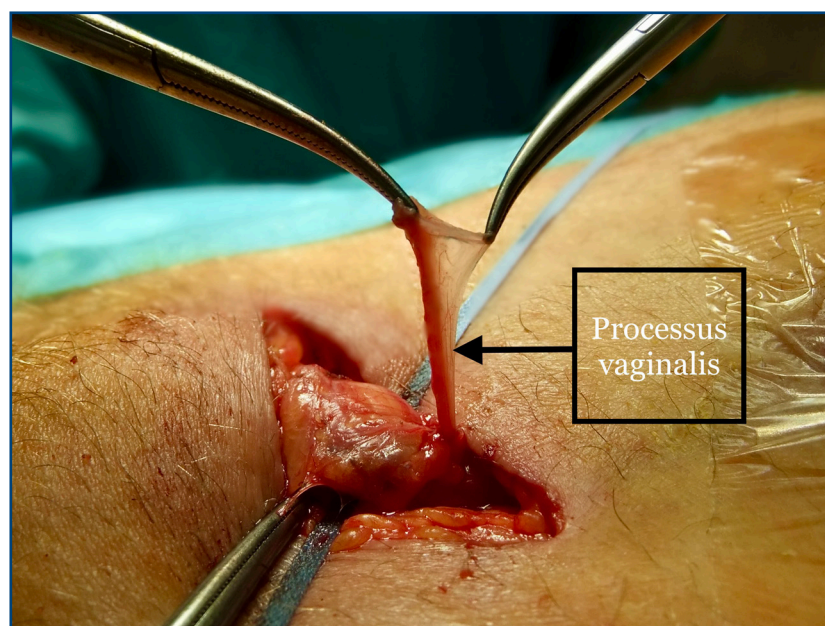
The indications for dialysis were a chronic renal failure in 45 cases (75%) and a heart failure in 15 cases (25%).

A catheter dysfunction was observed four times (6.5%):

- Twice due to insufficient drainage with two patients then referred for hemodialysis.
- Once for a painful pelvic symptomatology observed after insertion which was treated by catheter ablation and then secondary replacement of a peritoneal dialysis catheter.
- Once for a septic problem (abscess of the wall) treated by the withdrawal of the catheter with a subsequent repositioning.

A peritoneal dialysis catheter was removed due to the discovery of a pleuroperitoneal breach in a patient during the first dialysis sessions .

A patient was operated for a closure of the processus vaginalis after the detection of a hydrocele during the first dialysis session. (Figure 8)



↑ Figure 8. Exposure of the vaginal peritoneal canal before ligation

A patient was operated at the same time and under local anesthesia improved by intravenous sedation of the placement of a dialysis catheter and a unilateral inguinal hernia (Shouldice technique) with good anatomical and functional result.

So far no intraoperative complication has been encountered.

A patient is currently undergoing regular follow-up for the management of a granuloma at the site of the cutaneous emergence of the catheter, treated with a daily application of silver nitrate.

## DISCUSSION

Different techniques are used for the placement of a peritoneal dialysis catheter.

Laparoscopic and open surgery techniques are currently preferred for their levels of safety and satisfactory initial results [1].

The laparoscopic technique allows partial omentectomy, [2] or adhesiolysis during the catheter insertion into the peritoneal cavity to be performed in a less aggressive manner than open surgery. [3,4]

However, prospective randomized studies do not show any significant difference in the results comparing catheter insertions by laparoscopy and open surgery. [5,6]

A peritoneal dialysis catheter is made of three parts, intraperitoneal, subcutaneous and external. In 1985, Twardowski demonstrated that he obtained better catheter survival by modifying the subcutaneous segment to preform a curvature giving the shape of a swan neck which gave its name to this modified Tenckhoff catheter (Swan neck catheter) [7]. This has the theoretical advantage of preventing impurities from accumulating at the catheter exit port which then forms a downward funnel. The next modification consisted in increasing the intraperitoneal length to leave it coiled in place, the goal being to reduce the power of the jet when introducing the dialysate so as not to cause pain, and to limit movement [8]. These catheters are now the ones mainly used. However, not only did several studies recently confirmed by prospective randomized studies not evidence any advantage to coiled-ended catheters, but moreover the latters are more often responsible for mechanical problems or displacements [9,10]; for this reason we opted for the use of straight end Swan-Neck catheters, which gave us satisfactory results.

The percutaneous insertion technique has the advantage of being less invasive but carries a greater risk of incorrect catheter placement and intestinal perforation. However, in this same issue, a technique of percutaneous insertion carried out by the nephrologist at the bedside is reported with very good results as well.

In our opinion, laparoscopic and open surgery techniques can be used interchangeably in patients receiving a first catheter and who have no history of abdominal surgery. In case of a history of abdominal surgery, the laparoscopic technique is to be preferred because of the possibility of less aggressive adhesiolysis.

Our technique combines the efficiency and good results of open surgery while allowing the inser-

tion under local anesthesia potentiated by intravenous sedation, when patients are fragile. (25% of patients in our series).

We should again stress the need to respect the initial shape of the catheter and to ensure that its path under and trans-fascia is tangential and never slanted for more than 30 degrees as has been previously reported [11]

Limitation of this work: this study involves a small number of cases and is not randomized against another technique. Our goal was not to repeat the many studies already published and often contradictory on the different installation techniques. The dialogue with the nephrologist and an initial training of a morning with an experienced person, allowed us to obtain good results from the start by slightly modifying the technique to adapt it to our usual practice.

While many beginner centers encounter failures resulting from postoperative catheter malfunctions, especially when the peritoneal dialysis activity or the surgical team begins, it seemed important to us to bear witness to our experience which allowed us from our first catheter placements to have results that meet the nephrologist's expectations. This is a seemingly simple gesture for the surgeon, but one that requires full attention and a rigorous procedure as well as an ongoing dialogue with the nephrology team.

## CONCLUSION

We report our experience with a series of patients operated from the placement of peritoneal dialysis catheters through a mini midline laparotomy. A quarter of the operated patients had an indication of heart failure and their surgery was performed under local anesthesia potentiated by intravenous sedation. The surgical technique described appears to be safe and reproducible.

## ACKNOWLEDGMENTS

To the entire nursing team in the operating room and outpatient surgery department of the clinic Saint Michel Sainte Anne.

## CONFLICT OF INTEREST

*The authors declare no conflict of interest for this article.*

## REFERENCE

- 1- Peppelenbosch A, Van Kuijk WHM, Bouvy ND, Van der Sande FM, Tordoir JHM. Peritoneal dialysis catheter placement technique and complications. *NDT Plus*. 2008;1(1):23-28.
- 2- Ogunc G. Videolaparoscopy with omentopexy: A new technique to allow placement of a catheter for continuous ambulatory peritoneal dialysis. *Surgery Today*. 2001;31:942-944
- 3- Attaluri V, Lebeis C, Brethauer S, Rosenblatt S. Advanced laparoscopic techniques significantly improve function of peritoneal dialysis catheters. *Journal of the American College of Surgeons*. 2010;211:699-704.
- 4- Crabtree JH, Fishman A. A laparoscopic method for optimal peritoneal dialysis access. *The American Surgeon*. 2005;71:135-143.
- 5-. Wright MJ, Bel'eed K, Johnson BF, et al. Randomized prospective comparison of laparoscopic and open



peritoneal dialysis catheter insertion. *Perit Dial Int.* 1999;19:372–375.

6- van Laanen JHH, Cornelis T, Mees BM, Litjens EJ, van Loon MM, Tordoir JHM, Peppelenbosch AG. Randomized Controlled Trial Comparing Open Versus Laparoscopic Placement of a Peritoneal Dialysis Catheter and Outcomes: The CAPD I Trial. *Perit Dial Int.* 2018 Mar-Apr;38(2):104-112. doi: 10.3747/pdi.2017.00023.

7- Twardowski ZJ, Nolph KD, Khanna R, Prowant BF, Ryan LP. The need for a «swan neck» permanently bent, arcuate peritoneal dialysis catheter. *Perit Dial Bull*1985; 5:219-23.

8 - Twardowski ZJ, Prowant BF, Nichols WK, Nolph KD, Khanna R. Six-year experience with swan neck catheters. *Perit Dial Int.* 1992;12(4):384-9. PMID: 1420498.

9- David W Johnson 1 , Jennifer Wong, Kathryn J Wiggins, Robyn Kirwan, Anthony Griffin, John Preston, Daryl Wall, Scott B Campbell, Nicole M Isbel, David W Mudge, Carmel M Hawley, David L Nicol

A randomized controlled trial of coiled versus straight swan-neck Tenckhoff catheters in peritoneal dialysis patients

*Am J Kidney Dis.* 2006 Nov;48(5):812-21. doi: 10.1053/j.ajkd.2006.08.010.

10- Kai Ming Chow, Steve Siu Man Wong, Jack Kit Chung Ng, Yuk Lun Cheng, Chi Bon Leung, Wing Fai Pang, Winston Wing Shing Fung, Cheuk Chun Szeto, Philip Kam Tao Li

Straight Versus Coiled Peritoneal Dialysis Catheters: A Randomized Controlled Trial

*Am J Kidney Dis.* 2020 Jan;75(1):39-44. doi: 10.1053/j.ajkd.2019.05.024. Epub 2019 Aug 21.

11- Bammens B, Peeters D, Jaekers J, Claes KJ, Evenepoel P, Kuypers D, Meijers B, Naesens M, Vanrenterghem Y, Monbaliu D. Postimplantation X-ray parameters predict functional catheter problems in peritoneal dialysis. *Kidney Int.* 2014 Nov;86(5):1001-6.

available at : <https://doi.org/10.1038/ki.2014.203>

received 2021/10/11 accepted after revision 22021/11/01, published 2021/12/15



*Open Access This article is licensed under a Creative Commons Attribution 4.0 International*

*License, which permits use, sharing, adaptation, distribution and reproduction in any medium or format, as long as you give appropriate credit to the original author(s) and the source, provide a link to the Creative Commons license, and indicate if changes were made. The images or other third party material in this article are included in the article's Creative Commons license, unless indicated otherwise in a credit line to the material. If material is not included in the article's Creative Commons license and your intended use is not permitted by statutory regulation or exceeds the permitted use, you will need to obtain permission directly from the copyright holder. To view a copy of this license, visit <http://creativecommons.org/licenses/by/4.0/>.*